

Effects of Fenvalerate and Phosfolan-Treatment on the Histological Picture of Some Organs of Non-Pregnant and Pregnant Rats and Their Newborn

MOHAMED H. ABOU-EGLA, H.I. EL-SAYYAD, H.A. IBRAHIM and A.M.A. EL-SABAGH
*Zoology Department, Faculty of Science,
Mansoura University, Mansoura, Egypt*

ABSTRACT. Two insecticides were used in this study, one of them belongs to the synthetic pyrethroids (Fenvalerate), and the other one is an organophosphorus compounds (Phosfolan). Non-pregnant rats were given orally either fenvalerate (40 mg/kg day after day) or phosfolan (0.7 mg/kg day after day) for two and four months treatment. Pregnant rats were given fenvalerate (40:80 mg/kg per day) or phosfolan (0.7:2.3 mg/kg per day) from the first day of gestation till parturition. The organs investigated included the liver, kidney, ovary and uterus.

The present results are summarised as follows :

1. Liver

Both non-pregnant and pregnant rats showed centrilobular necrosis, nuclear degeneration, fatty change, bile duct proliferation and round cell infiltration post either fenvalerate or phosfolan-treatment. The hepatitis increased with the dose and period of treatment. Newborn delivered from either fenvalerate or phosfolan-treated animals showed necrotic patches of hepatocytes associated with round cell infiltration.

2. Kidney

Two months treatment of non-pregnant rats with either fenvalerate or phosfolan showed hyaline degeneration, deformed renal tubules, cyst formation, sclerotic glomeruli as well as interstitial fibrosis. Phosfolan-treatment caused the most marked effects. Similar histopathological lesions were observed in pregnant rats. Newborn delivered from fenvalerate-treated mothers showed damaged renal tubular epithelium in lower dose treatment, deformed tubules and Malpighian bodies after higher dose-treatments. However, both doses of phosfolan-treatment caused deformation of renal tubules with vanishing of the majority of them.

3. Ovary

Both fenvalerate and phosfolan-treatment caused a decrease in the number of ovarian follicles. Four months after fenvalerate-treatment, the ovarian follicles were replaced by hyaline fibrosis.

4. Uterus

Both insecticides used induced vesicular atrophy of endometrial glands which seemed to be non-secretory. Also, internal haemorrhagic spots were detected.

Introduction

Pyrethroids and organophosphorus compounds have a wide spectrum of insecticidal potency and produce acute toxicosis in vertebrates manifested by the inhibition of acetylcholine esterase (Fikes^[1] and Valentine^[2]). A variety of these compounds were noted to be mutagenic and produce acute toxicity characterized by salivation, ataxia, convulsion and central nervous system depressants (Anonymous^[3] and Williamson *et al.*^[4]). Twenty cases of paraquat-intoxication revealed edematous denaturation and necrosis of bile duct epithelium of the liver (Matsumoto *et al.*^[5]). He-F *et al.*^[6] reported abnormal facial sensations, dizziness, fatigue and miliary red papules in 199 workers engaged in handling pyrethroids.

Treating experimental animals with a wide range of compound including endosulfan (Gupta and Chandra^[7]), foschlor (Stazyc^[8]), fenvalerate (Anonymous^[9], Hend and Butterworth^[10] and El-Sayyad and El-Shershaby^[11]), cypermethrin (Mc-Ausland *et al.*^[12]), thimet (Saxena and Sarin^[13]), chlordecone, mirex or photomirex (Curtis *et al.*^[14]) or fenvalerate and methomyl (El-Kashory^[15]) leads to the production of hepatic lesions with lipid accumulation.

Treating mice with fenvalerate (El-Sayyad and El-Shershaby^[11]) and rat with cypermethrin (Mc-Ausland^[12]) were found to induce tubular and cortical necrosis and interstitial chronic inflammatory infiltration in renal tissues.

The present work deals with the effects of fenvalerate (synthetic pyrethroid) and phosfolan (organophosphorus) on the histologic picture of liver and kidney of non-pregnant and pregnant rats and their newborn. Ovary and uterus of non-pregnants were also examined.

Material and Methods

Eighty healthy female rats (80-100 g body weight), were used during experimentation. The animals were kept under good ventilation and adequate standard diet for at least one month prior to the experimental work. Water was allowed ad-libitum. The animals were divided into two main categories. In the first category, the virgin females were separated from males to prevent the outcome of pregnancy. In the second category, each male was housed with three females in a separate cage for one night and if observing a vaginal plugs as well as spermatozoa in a vaginal smear in the next morning, the induction of pregnancy and zero date of gestation were deter-

mined (Billet and Wild^[16]). Every category was divided into the following four groups, each composed of ten animals :

- The first control virgin group; each animal was intragastrically administered with 0.1 ml corn oil-free from the insecticide day after day for two and four months.
- The second treated virgin group; each animal was intragastrically administered with 0.7 mg *phosfolan (in 0.1 ml corn oil)/kg body weight (b.w.) day after day for two and four months.
- The third treated virgin group; each one was intragastrically administered with 40 mg **fenvalerate/kg b.w. day after day for two and four months.
- The fourth control pregnant rats; each animal was intragastrically administered with daily doses of 0.1 ml corn oil free from the insecticides from zero date of gestation till parturition.
- The fifth treated pregnant group; each animal was intragastrically administered with daily doses of 0.7 mg phosfolan/kg b.w., from zero date of gestation till parturition.
- The sixth treated pregnant group; each animal was intragastrically administered with daily doses of 2.3 mg phosfolan/kg b.w., from zero date of gestation till parturition.
- The seventh treated pregnant group; each animal was intragastrically administered with daily doses of 40 mg fenvalerate/kg b.w. from zero date of gestation till parturition.
- The eighth treated pregnant group; each animal was intragastrically administered with daily doses of 80 mg fenvalerate/kg b.w. from zero date of gestation till delivery.

At the treatment, the insecticides-treated rats were sacrificed by decapitation. Immediately after dissection, samples of liver, kidney, uterus, and ovary were fixed in 10% formol saline. The fixed specimens were dehydrated in ascending grades in alcohol, cleared in xylol and embedded in molten paraffin wax 58-60°C. Five μ thick tissue sections were stained with haematoxylin and eosin prior to microscopic examination. Tissues from control rats, free from insecticides treatment were examined in the same way.

Results

1. Non-Pregnant Rats

1.1. Liver

Two months after fenvalerate-treatment (40 mg/kg b.w. day after day), the liver tissue showed hypertrophy of hepatocytes with either pycnotised or karyolysed nuc-

*Phosfolan (Diethyl 1,3-dithidan-2-ylidenephosphor-amidate), active ingredient (71%) of organophosphorus insecticides produced by agricultural division, American company.

**Fenvalerate (&-cyano-phenoxy benzyl-isopropyl-p-chlorophenyl acetate), active ingredient (95.5%) synthetic pyrethroid produced by Sumitomo Chemical Company, Japan.

For experimental use, the above mentioned insecticides were dissolved in corn oil of highest purity.

lei, round cell infiltration, dilated sinuses and centrolibular necrosis (Fig. 1B1). In addition, severe coagulative necrosis of hepatocytes, associated with vascular congestion were detected after four months treatment (Fig. 1B2).

Phosfolan-treatment (0.7 mg/kg day after day) led to the production of fine vacuolation of hepatocytes (fatty metamorphosis) with various degree of nuclear degeneration (pycnosis and karyorrhexis) by two months treatment (Fig. 1C1). However, four months treatment revealed the appearance of fibrous connective tissue in the portal region. Spotty patches of centrolibular necrosis, lymphocytic infiltration, fatty change (accumulation of lipid within hepatocytes) and massive nuclear damage were also detected (Fig. 1C2). Compare with the control.

1.2. Kidney

Fenvalerate-treatment (40 mg/kg day after day) induced focal atrophy of renal tubules with interstitial inflammation. Most of these tubules appear dilated with either thinned or damaged epithelial lining cells. Some renal tubules showed thickening of their basement membrane. Also, necrotic Malpighian bodies and cystic change in the kidney was also detected after two months treatment (Fig. 2B1). In addition, a marked hyalinization, thickened basement membrane of renal tubules, interstitial inflammation, congestion of the glomeruli and focal cortical necrosis with a limited tubular loss were seen after four months treatment (Fig. 2B2).

Two months post phosfolan-treatment (0.7 mg/kg day after day) produced internal haemorrhage, sclerotic glomeruli with thickened basement membrane, hyaline degeneration and detached epithelial cells lining the renal tubules with spotty patches of necrosis (Fig. 2C1). Besides, four months treatment revealed swelling of Bowman's capsules with sclerotic glomeruli and the renal tubules become atrophied and widely separated from each other (Fig. 2C2) in a comparison with the control (Fig. 2A).

1.3. Female Genital Organs

In two months fenvalerate-treatment, the uterine tissue showed a slight differentiation of glandular epithelial cells lining the endometrial glands (Fig. 3B1). Four months treatment revealed partial loss of endometrial glands and internal haemorrhage. Fibrous sheath formation was also detected in the endometrium (Fig. 3B2). By two months, phosfolan-treatment induced vesicular atrophy of endometrial glands. Internal haemorrhagic spots were also seen (Fig. 3C1).

Two months fenvalerate-treatment showed a numerical decrease of ovarian follicles. The follicular cells showed a partial necrosis and slight differentiation (Fig. 4B1). Treatment, the ovary showed numerous spherical shaped structures in the place of previous ovarian follicles (Fig. 4B2). By two months phosfolan-treatment, the ovary showed a damaged ovarian follicles associated with necrotic patches of follicular cells (Fig. 4C1). Four months phosfolan-treatment caused much more damaged and atropy of ovarian follicles (Fig. 4C2) in comparison with control (Fig. 4A).

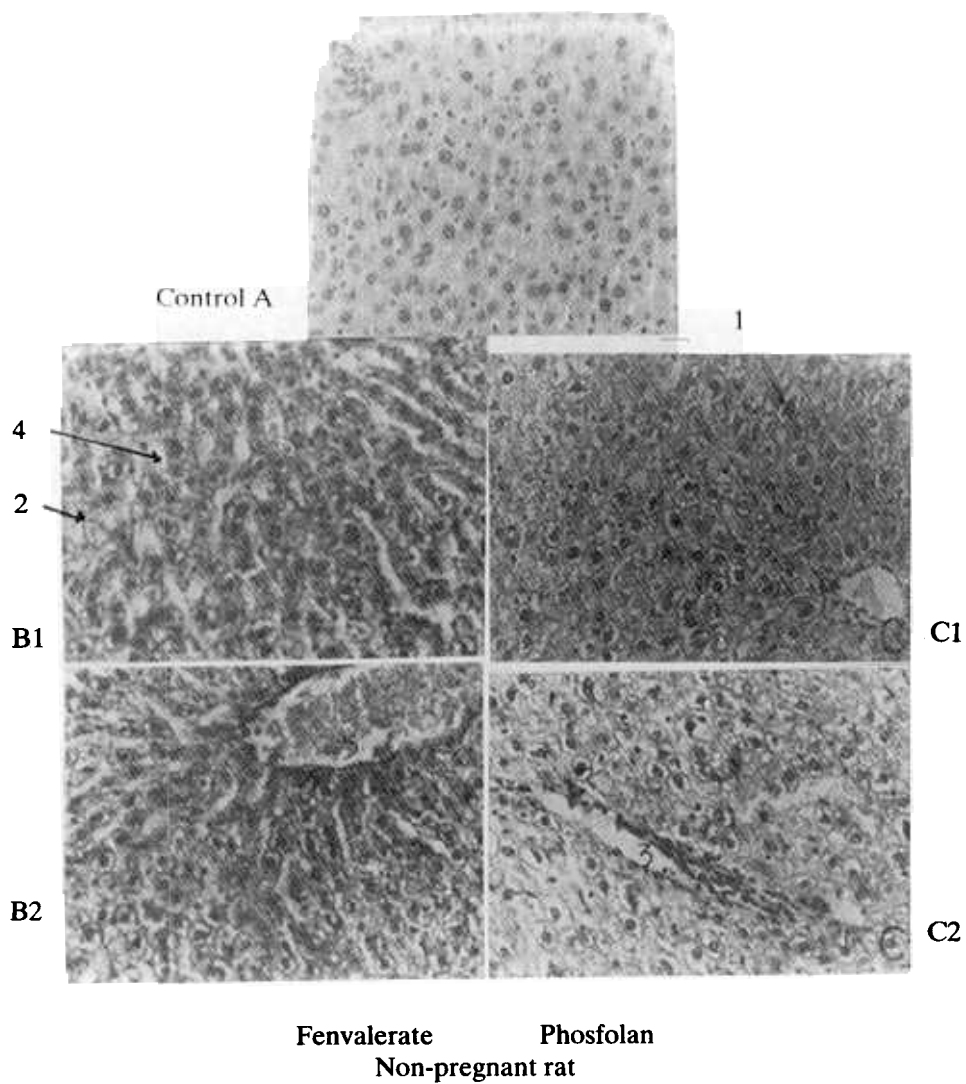


FIG. 1. Histologic section in liver of non-pregnant rats.

A. Control of corn-oil-treated.

B1. Two months fenvalerate-treatment.

B2. Four months fenvalerate-treatment.

C1. Two months phosfolan-treatment.

C2. Four months phosfolan-treatment.

Note: 1. Pyknosis, 2. Karyorrhexis, 3. Lymphocytic infiltration, 4. Dilated sinuses, 5. Congested blood vessel.

H.E. × 250

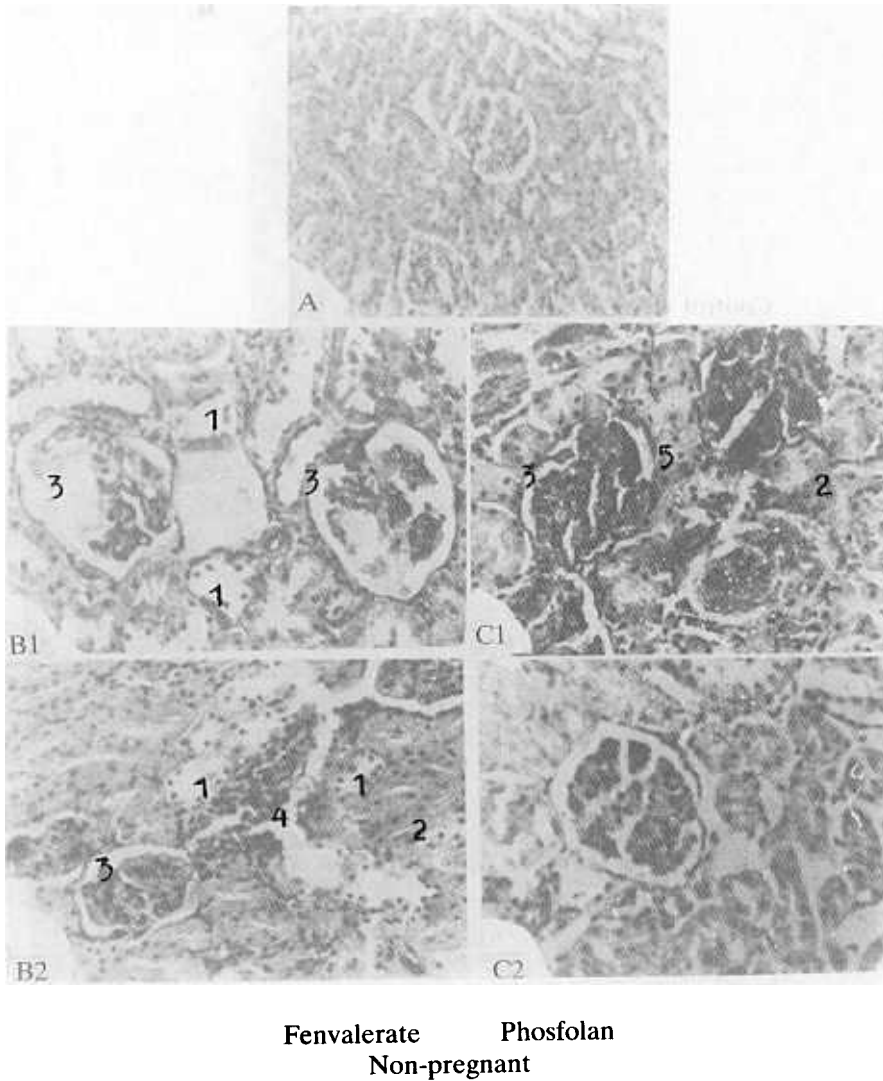


FIG. 2. Histologic section in kidney of non-pregnant rat.

- A. Control corn-oil-treatment.
- B1. Two months fenvalerate-treatment.
- B2. Four months fenvalerate-treatment.
- C1. Two months phosfolan-treatment.
- C2. Four months phosfolan-treatment.

Note: 1. Necrosis of epithelial cells lining renal tubules, 2. Atrophied renal tubules, 3. Sclerotic glomeruli, 4. Interstitial inflammation, 5. Hyaline degeneration.

H.E. × 250

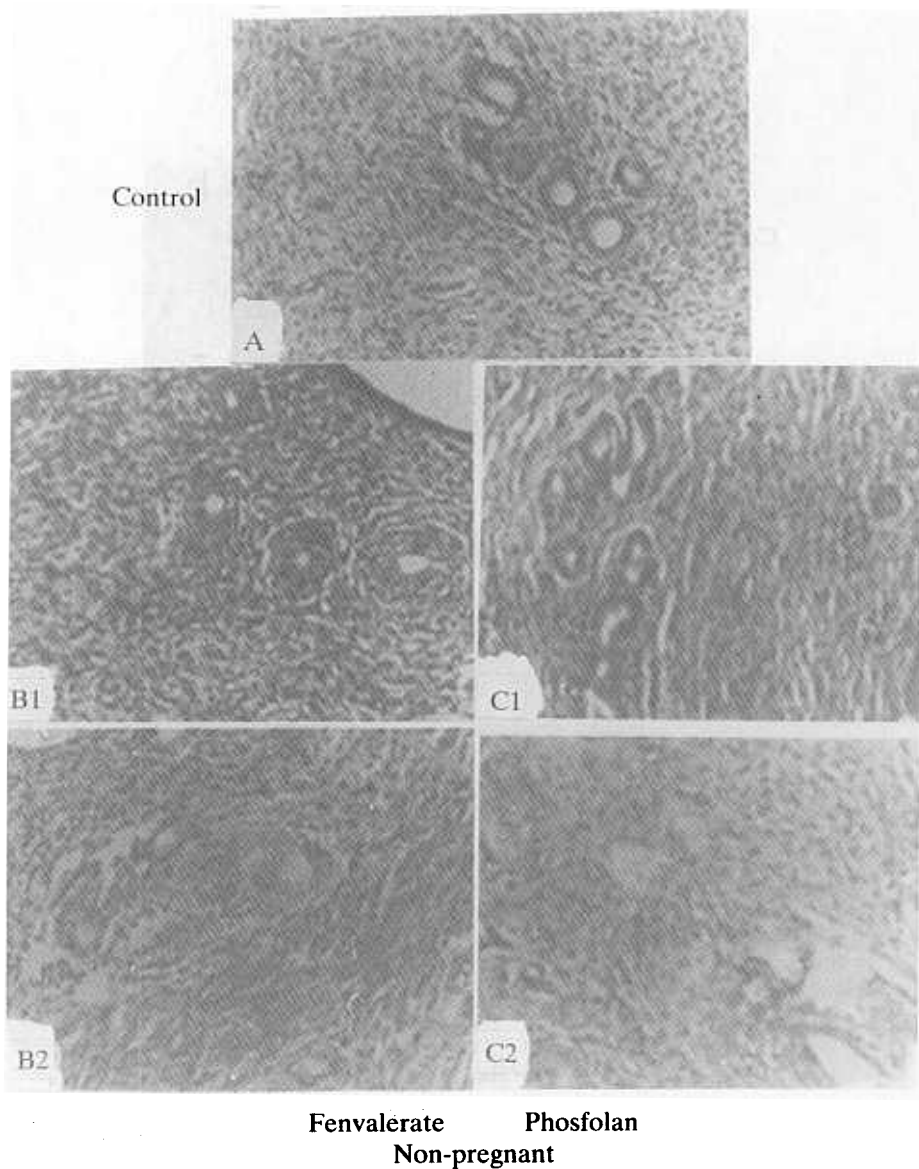


FIG. 3. Histologic section in uterine tissues of non-pregnant rats.

- A. Control corn-oil-treatment.
- B1. Two months fenvalerate-treatment.
- B2. Four months fenvalerate-treatment.
- C1. Two months phosfolan-treatment.
- C2. Four months phosfolan-treatment.

Note: Collapsed endometrial glands in both two months-treatment. However, four months-treatment showed complete loss of the majority of glands.

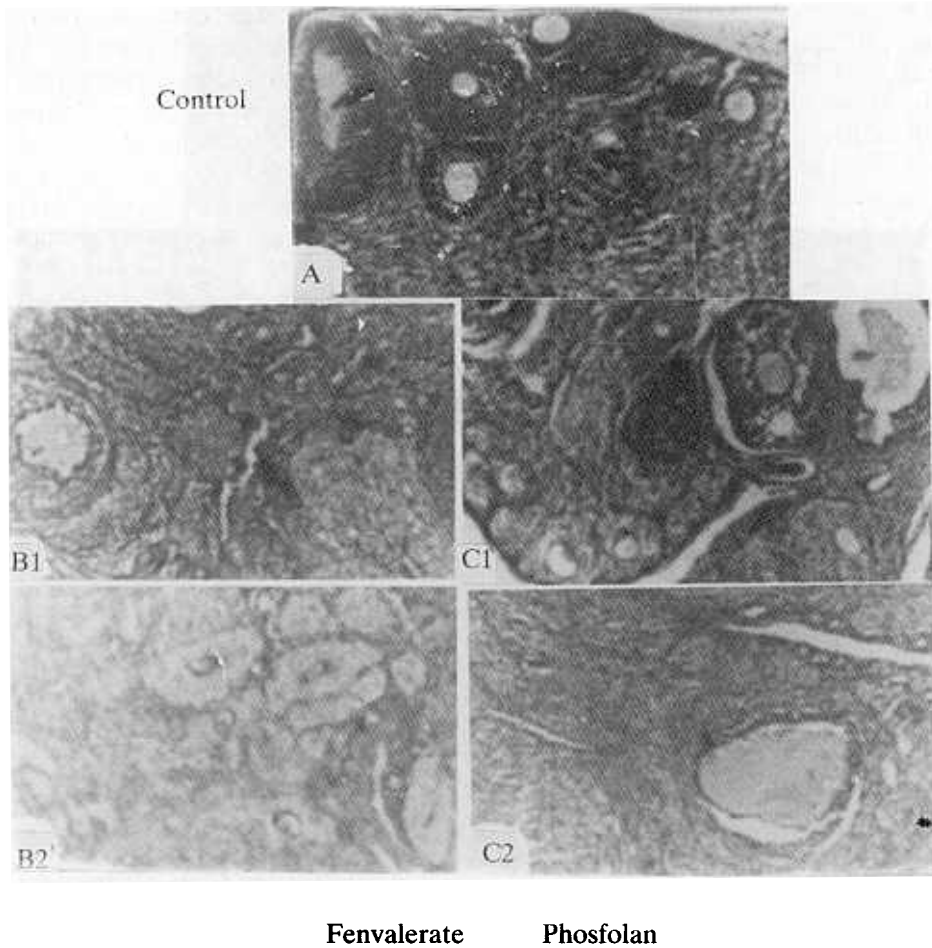


FIG. 4. Histologic section in the ovary of non-pregnant rats.

- A. Control of corn-oil-treatment.
- B1. Two months fenvalerate-treatment.
- B2. Four months fenvalerate-treatment.
- C1. Two months phosfolan-treatment.
- C2. Four months phosfolan-treatment.

Note: A numerical decrease of ovarian follicles in both two months treatments. The ovarian follicles degenerated in four months phosfolan-treatment and replaced by spherical shallow-shaped structures in fenvalerate-treatment.

H.E. × 250

2. Pregnant Rats

2.1. Liver

Daily intragastric administration of 40 mg fenvalerate/kg b.w. to pregnant rats from the onset of pregnancy till parturition was found to cause obliteration of bile duct proliferation, centrolibular necrosis, dilated sinuses, round cell infiltration and nuclear change with either pycnosis or karyolysis (Fig. 5A1). Newborns delivered from those treated mothers showed massive degeneration of hepatocytes with round cell infiltration (Fig. 6B1). However, 80 mg fenvalerate-treatment with the same route, led to the production of focal foci of hepatic necrosis, fine vacuolation of hepatocytes with nuclear damage and edematous and congested blood vessels (Fig. 5A2). Fenvalerate-treatment delivered newborn (80 mg/kg) showed an increased round cell infiltration in the area of hepatic necrosis (Fig. 6B2).

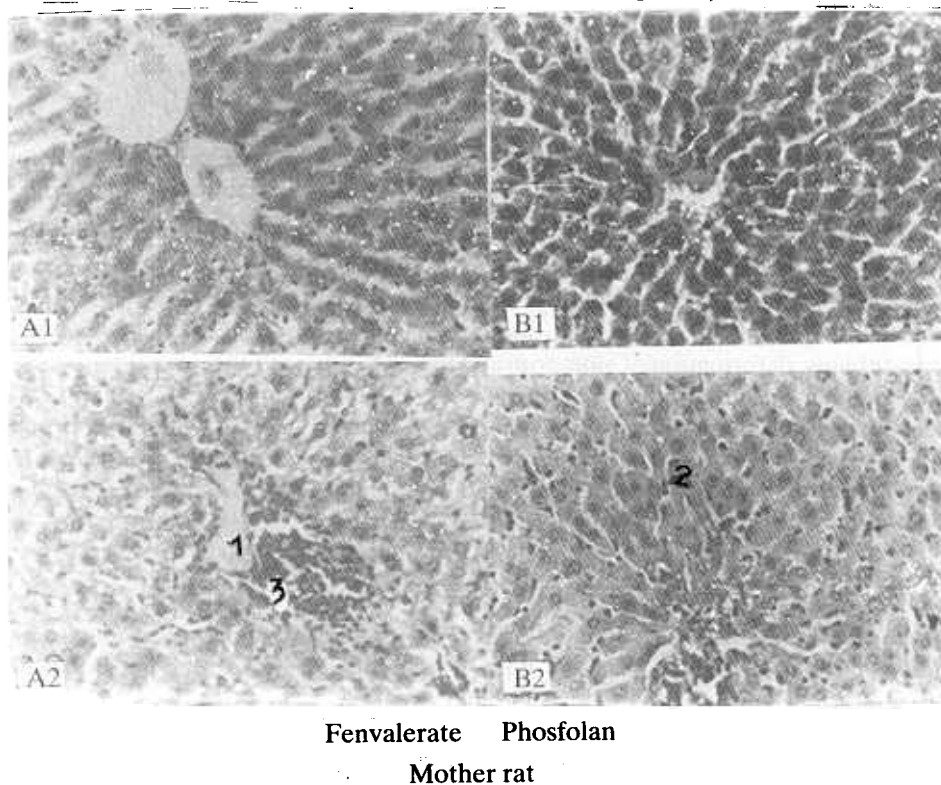


FIG. 5. Histologic section in the liver of pregnant rats.

A1. 40 mg/kg fenvalerate-treatment.

A2. 80 mg/kg fenvalerate-treatment.

B1. 0.7 mg/kg phosfolan-treatment.

B2. 2.3 mg/kg phosfolan-treatment.

Note: 1. Oedematous blood vessel, 2. Hypertrophied kupffer cells, 3. Focal hepatic necrosis. Regard the control in Fig. 1.

H.E. × 250

Daily oral administration of 0.7 mg phosfolan/kg b.w. as mentioned was found to induce dilated sinuses, congested blood vessel and slight degeneration of hepatocytes (Fig. 5B1). Newborn delivered from those rats showed necrotic liver cells associated with round cell infiltration (Fig. 6C1). In addition, 2.3 mg phosfolan-treatment/kg kg b.w. caused hypertrophy of kupffer cells with a slight foci of necrosis and round cell infiltration in the pregnant's liver (Fig. 5B2). Treated newborn from those rats showed deteriorated liver plates with a considerable loss of its architecture shape. A damaged hepatocytes associated with round cell infiltration (Fig. 6C2). Regard the control (Fig. 6A).

2.2. Kidney

Daily intragastric administration of 40 mg fenvalerate/kg b.w. to pregnant, from the onset of gestation till parturition, was found to produce interstitial fibrosis, hyaline degeneration, sclerotic glomeruli and severe tubular loss (Fig. 7B1). Newborn delivered from those treated mothers showed swelling of Bowman's capsules and necrotic patches of epithelial cells lining renal tubules (Fig. 8B1). Higher dose fenvalerate treatment (80 mg/kg b.w.) showed similar drastic effect as mentioned above as well as hyperplasia of the epithelial lining the renal tubules which become more dilated (Fig. 7B2). Newborn of those treated showed malformation of renal tubules and Malpighian bodies (Fig. 8B2).

Treating pregnant rats with 0.7 mg phosfolan/kg b.w. as mentioned marked hyaline degeneration with peculiar glomerular and renal atrophy (Fig. 7C1). Newborn delivered from those treated mothers degeneration of epithelial cells lining renal tubules, deformation of glomeruli and loss of the majority of renal tubules (Fig. 8C1). Higher dose-treatment (2.3 mg/kg b.w.) induced swelling of Bowman's capsules, sclerosis of glomeruli and atrophy of renal tubules with detachment of epithelial lining cells (Fig. 7C2). Newborn delivered from those treated mothers showed similar histopathological finding as previously mentioned in the above treatment (Fig. 8C2).

Discussion

The results obtained from this study, revealed that oral administration of fenvalerate-synthetic pyrethroid (40 mg/kg body weight, day after day) or phosfolan-organophosphorus (0.7 mg/kg body weight, day after day) to non-pregnant rats for two and four months led to centrolibular necrosis, hypertrophy of Kupffer cells, nuclear degeneration (pynosis or karyorrhesis), fatty change, bile duct proliferation and round cell infiltration. The hepatitis increased with the length of treatment. Similar histopathologic findings were detected in pregnant rats daily dosed with fenvalerate (40 or 80 mg/kg body weight) or phosfolan (0.7 mg or 2.3 mg/kg body weight) throughout gestation.

The present findings support the work of Anonymous^[9], Hend and Butterworth^[10] and El-Kashory^[15] after treating mice and rats with fenvalerate of different dose-treatment. Also, similar results have been achieved by Gupta and Chandra^[7].

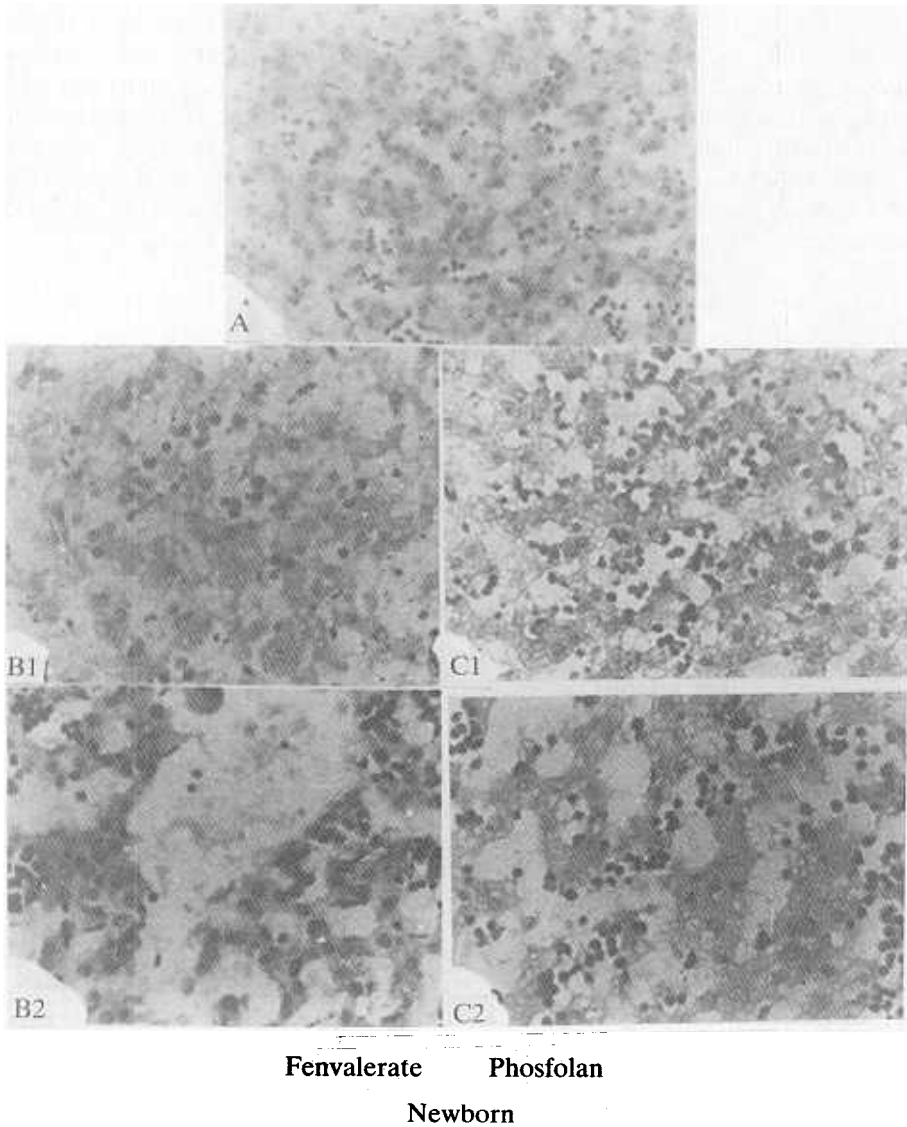


FIG. 6. Histologic section in liver of rat newborn 1 day-age.

- A. Control corn oil-treatment.
- B1. 40 mg/kg fenvalerate-treatment.
- B2. 80 mg/kg fenvalerate-treatment.
- C1. 0.7 mg/kg phosfolan-treatment.
- C2. 2.3 mg/kg phosfolan-treatment.

Note: Partial damaged hepatocytes with round cell infiltration in low doses-treatment. Higher doses-treatment revealed intensive necrosis with losing of its architecture structure.

H.E. × 250

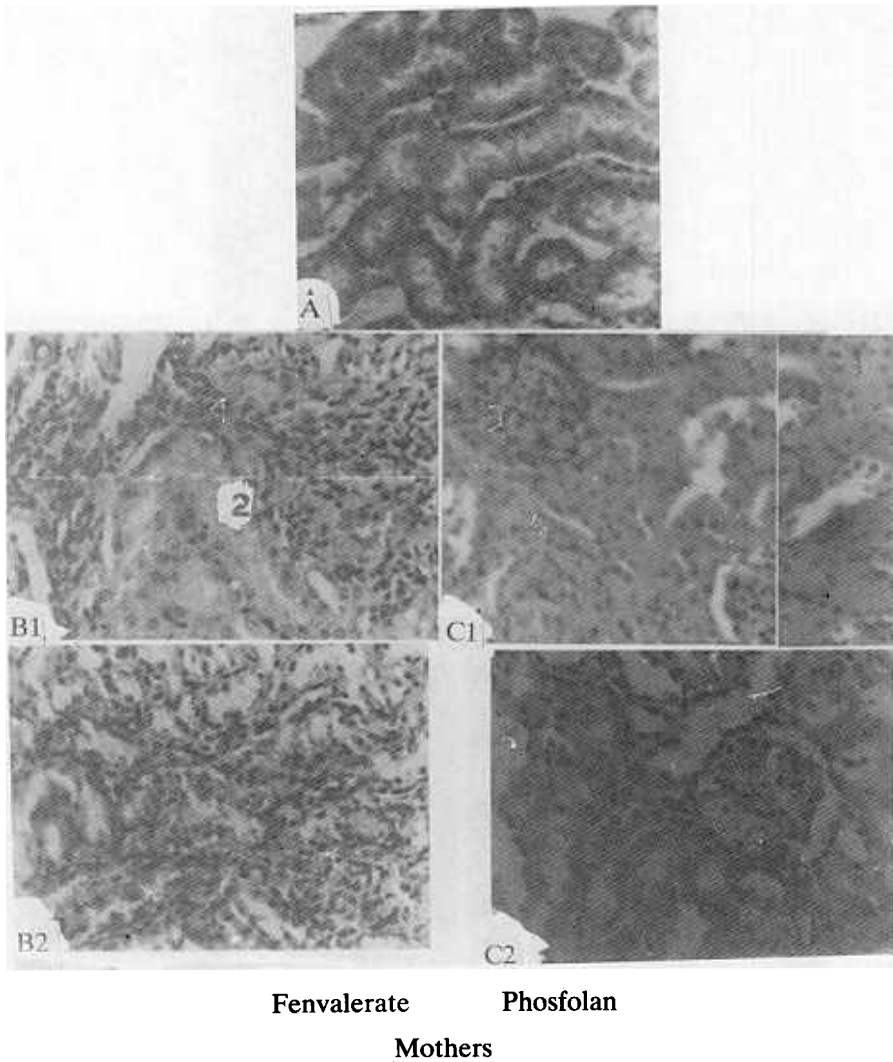
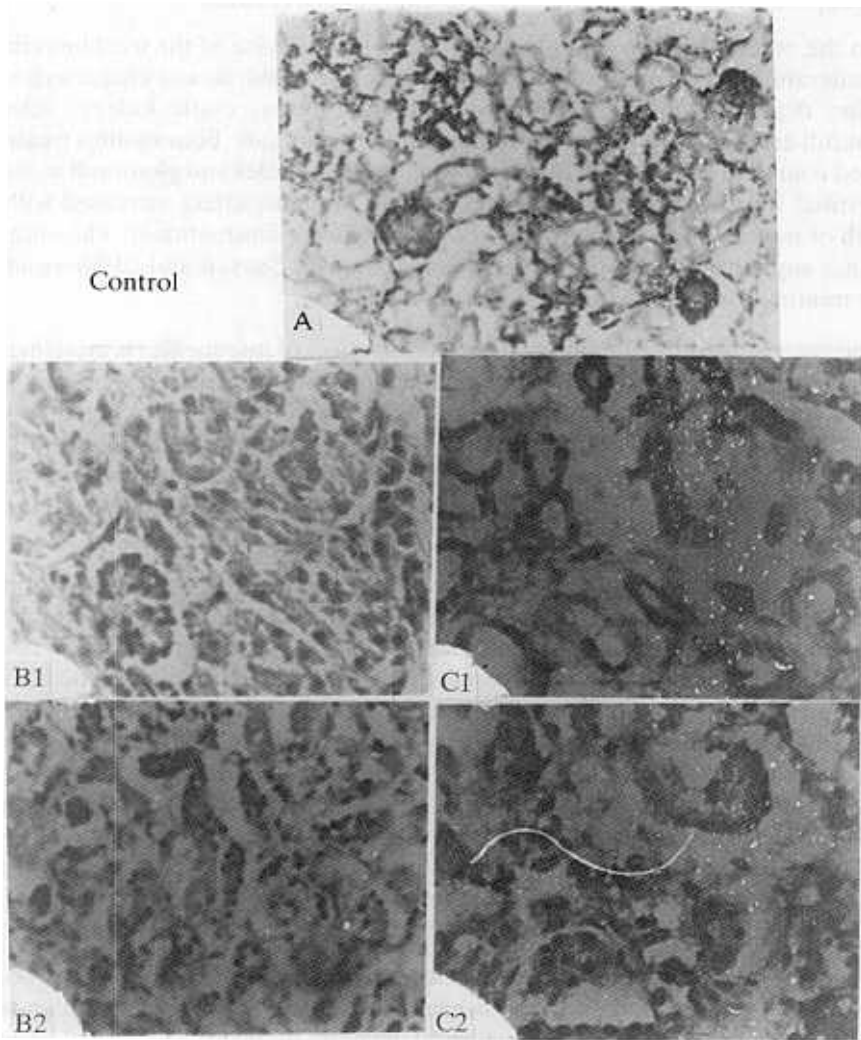


FIG. 7. Histologic section in kidney of pregnant rats.

- A. Control corn-oil-treatment.
- B1. 40 mg/kg fenvalerate-treatment.
- B2. 80 mg/kg fenvalerate-treatment.
- C1. 0.7 mg/kg phosfolan-treatment.
- C2. 2.3 mg/kg phosfolan-treatment.

Note: 1. Interstitial fibrosis, 2. Degenerated tubule, 3. Nephrosis, 4. Hyaline degeneration.

H.E. × 250



Fenvalerate Phosfolan
Newborn

FIG. 8. Histologic section in kidney of rat newborn 1 day-age.

- A. Control corn oil-treatment.
- B1. 40 mg/kg fenvalerate-treatment.
- B2. 80 mg/kg fenvalerate-treatment.
- C1. 0.7 mg/kg phosfolan-treatment.
- C2. 2.3 mg/kg phosfolan-treatment.

Note: Malformation of renal tubules which more detected in phosfolan-treatment.

H.E. × 250

Mathur^[17], Saxena and Sarin^[13], Curtis *et al.*^[14], Matsumoto *et al.*^[5] following treatment experimental animals with different kinds of insecticides.

On the other hand, two months treatment with each one of the used insecticides (fenvalerate or phosfolan) revealed toxic effect on renal tissues characterized by hyaline degeneration, focal atrophy of renal tubules, cystic kidney, sclerotic glomeruli and interstitial inflammation in non-pregnant rats. Four months treatment caused complete atrophy and degeneration of renal tubules and glomeruli as well as interstitial fibrosis and sclerosis. The observed dramatic effect increased with the length of treatment and was more marked post phosfolan-treatment. The observed findings supported the work of El-Kashory^[15] and El-Sayyad and El-Shershaby^[11] after treating mice with different doses of fenvalerate.

The present work has demonstrated that the effect of insecticides is more marked in renal than in hepatic tissue. The renal tissues of treated pregnant rats showed similar histopathologic findings as in non-pregnants. Newborn delivered from fenvalerate-treated rats showed a damaged epithelial cells lining renal tubules in lower doses and deformed tubules and Malpighian bodies after higher doses. However, both doses of phosfolan-treatment caused deformation of renal tubules with the loss of the majority of them.

The damages of renal and hepatic tissues were diagnosed by significant alterations of alkaline phosphatase activity (Saxena and Sarin^[13]) and reported in liver and kidneys of non-pregnants, pregnant and delivered newborn post fenvalerate or phosfolan-treatment (El-Sabagh^[18]). The susceptibility of renal tissues to insecticides intoxication may be attributed to the bio-transformation of insecticide into different metabolites by liver microsomes (Declotire *et al.*^[19]) which exert their toxic effect. Soderlund and Casida^[20] attributed the selective toxicity of fenvalerate to its ability to accumulate in tissues resulting from the presence of α -cyano-3-phenoxybenzyle esters groups which are less susceptible to metabolic attack. El-Toukhy *et al.*^[21] observed that the dimethoate, carbaryl and permethrin induced disturbances in hepatic L-tryptophan metabolism leading to accumulation of tryptophan metabolites which may be an etiological factor in the occurrence of bladder cancer.

In addition, the fenvalerate-treatment caused a numerical decrease of ovarian follicles in low doses and complete absence in higher doses. However, phosfolan-treatment, revealed only atrophy and numerical decrease of the follicles. Also, vesicular atrophy and non-secretory function of endometrial glands were detected in both doses of the used insecticides. Treating Japanese quail with chloredecone was found to cause keratinization and hyperplasia of uterine glands (Eroschenko and Wilson^[22]). Treating Japanese quail eggs with lindane (Lutz-Ostertag^[23]) or DDT (Danielle^[24]) was found to produce a repercussion on fertility and egg production as well as gonadic germ deficit. Nigam *et al.*^[25] observed a numerical reduction of corpora lutea in ovaries of DDT treated female mice.

In conclusion, this study revealed that fenvalerate and phosfolan, as individual pesticides, showed harmful effects on liver, kidney, ovary and uterus of non-pre-

gnant rats. Liver and kidney of pregnant rats and their newborn showed similar dramatic effect. The renal tissues were highly susceptible to intoxication than the others which may be represent an etiological factor that co-operated in the induction of renal failure.

References

- [1] Fikes, J.D., Toxicology of selected pesticides, drugs and chemicals. Organophosphate and carbamate insecticides, *Vet. Clin. North Am. Small Anim. Pract.* **20**(2): 353-513 (1990).
- [2] Valentine, W.M., Toxicology of selected pesticides, drugs and chemicals. Pyrethrin and pyrethroid insecticides, *Vet. Clin. North Am. Small Anim. Pract.* **20**(2): 375-384 (1990).
- [3] Anonymous, Organophosphorus insecticides. A general introduction. Environ. Health Criteria, *International Programme on Chemical Safety, World Health Organization, Geneva*, **63**: 1-181 (1989).
- [4] Williamson, E.G., Long, S.F., Kallman, M.J. and Wilson, M.C., A comparative analysis of the acute toxicity of technical grade pyrethroid insecticides and their commercial formulations, *Exotoxicology and Environmental Safety* **18**(1): 27-34 (1989).
- [5] Matsumoto, S., Matsumori, H., Kuwabara, N., Fukula, Y. and Ariwa, R., Histopathological studies on the disturbance of bile ducts due to paraquat, *Acta Hepatol. Japn.* **22**(2): 309 (1981).
- [6] He, F., Sun, J., Han, K., Yao, P., Wang, S. and Liu, L., Effects of pyrethroid insecticides on subjects engaged in packing of pyrethroids, *Br. J. Ind. Med.* **45**(8): 548-551 (1988).
- [7] Gupta, J.D. and Chandra, S.V., The toxicity of endosulfan in rabbits. *Bull. Environ. Contam. Toxicol.* **14**(5): 513 (1988).
- [8] Stazyc, J., Experimental studies on the effect of foschlor on primarily damaged liver. *Ann. Univ. Mariae Curie. Sklodowska, Sec. D. Med.* **31**: 237-244.
- [9] Anonymous, *Shell Research Ltd. TLGR 0042-75 (At 51-003-S)*, Quoted from M.Sc. thesis, El-Kashory, Fac. Agric., Ain Shams Univ. (1984).
- [10] Hend, R.W. and Butterworth, S.G., *Toxicity studies on the insecticides WL-43467, A three monthly feeding study in rats*, Unpublished report from Shell Research Ltd. Submitted from the international chemical company (1976).
- [11] El-Sayyad, H.I. and El-Shershaby, E.M., Histological and biochemical studies on the effect of fenvalerate on some organs of mice, *Mansoura Sci. Bull.* **13**(1): 120-135 (1986).
- [12] Mc-Ausland, H.E., Butterworth, S.T.G and Hunt, P.F., *Toxicity studies on the insecticides WL-43467. A two year feeding study in rats*. Unpublished report from Shell Research Ltd. (1978).
- [13] Saxena, A.K. and Sarin, K., Histopathological and biochemical changes in the liver and testis of desert gerbilus after repeated exposure of thinet (phorate), *J. Toxicology* **18**: 133-144 (1980).
- [14] Curtis, L.R., Thureson-Klein, A.K. and Mehenic, H.M., Ultrastructural and biochemical correlates of the specificity of chlordecone potentiated carbon-tetrachloride hepatotoxicity, *J. Toxicol. Environ. Health* **7**(3-4): 499-517 (1981).
- [15] El-Kashory, A.A., *Toxicological effects of certain pesticides on internal organs and metabolism of rats*, M.Sc. Thesis, Fac. Agric., Ain. Shams Univ. (1984).
- [16] Billet, F.S. and Wild, A.S., *Practical studies of animal development*, Published by G.B. Willmer Brothers Ltd., Birkenhead (1975).
- [17] Mathur, D.S., Histopathological changes in the liver of fish resulting from exposure to certain insecticides, *Toxicology* **17**(5): 118 (1979).
- [18] El-Sabagh, A.M.A., *Effects of insecticides on the mothers and newborn rats*. Ph.D. Thesis, Fac. Sci., Mansoura Univ., Egypt (1986).
- [19] Decloitre, F., Chavaeu, J., Benoit, A. and Martin, M., Metabolism and *in vitro* binding of several organochlorine and organophosphate insecticides. To calf thymous DNA and rat liver microsomal proteins. *C.R.A. Acad. Science* **280**(8): 107-130.
- [20] Soderlund, D.M. and Casida, J.E., Effect of pyrethroid structure on rate of hydrolysis by mouse liver microsomal enzymes, *Pesticides Bioch. Physiol.* **7**(4): 391 (1977).
- [21] El-Toukhy, M.A., Ebid, S.A., Hassan, A.A. and El-Swedy, S.M., *In vivo* studies on the effect of

- some insecticides on the hepatic activities of L-tryptophan 2, 3-dioxygenase and pyridoxal phosphokinase of male mice, *J. Environ. Sci. and Health. Part B. Food Contamination and Agricultural Waste. B* **24**(3): 265-276 (1989).
- [22] **Eroschenko, V.B. and Wilson, W.O.**, Cellular changes in the gonads, liver and adrenal glands of Japanese quail as affected by the insecticide kepone, *Toxicol. Appl. Pharmacol.* **31**: 491-502 (1975).
- [23] **Lutz-Ostertag, Y.**, Lindane effects in several generations on the fertility and embryonic mortality levels, the hatchability, the egg production and the egg and chicken weight, *Arch. Anat.* **57**(2): 269-282 (1974).
- [24] **Danielle, D.**, Effect of DDT on the gonadic population in quail embryos from five successive generations, *C.R. Hebd. Seances Acad. Sci. Ser. D.* **280**(8): 107-130 (1975).
- [25] **Nigam, S.K., Kahyap, S.K., Kumar, A., Gupta, R.C. and Kannik, A.B.**, Effect of technical grade DDT on neonatal mice, *Indian J. Med. Res.* **65**(4): 576-578 (1977).

تأثير المعاملة بالفينفاليرات والفوسفولان على الصورة النسيجية لبعض الأعضاء في عذاري وحوامل جرذان الرات وأبنائهم

محمد حسن أبو عجلة ، حسن إبراهيم الصياد ، حمدي عبد الحميد إبراهيم و أمورة أبو النجا الصباغ
قسم علم الحيوان ، كلية العلوم ، جامعة المنصورة ، المنصورة ، مصر

المستخلص . استخدمت في هذه الدراسة مبيدين أحدهما ينتمي إلى البيروثويدات التخليقية (الفينفاليرات) والآخر إلى المركبات الفوسفورية (فوسفولان) .

أعطيت عذاري الرات جرعات فمية من الفينفاليرات (٤٠ مجم /كجم يوماً بعد يوم) أو الفوسفولان (٠,٧ مجم /كجم يوم بعد يوم) لمدة شهرين وأربعة أشهر ، بينما أعطيت حوامل الرات جرعات فمية من الفينفاليرات (٤٠ و ٨٠ مجم /كجم يومياً) أو الفوسفولان (٠,٧ : ٢,٣ مجم /كجم يومياً) من اليوم الأول للحمل حتى الولادة وتناولت الدراسة الفحوص النسيجية لكل من الكبد - الكلى - المبيض - الرحم .

ويمكن تلخيص النتائج على النحو التالي

١ - الكبد

أظهر نسيج الكبد في كل من عذاري وجرذان الرات وجود تآكل في مراكز فصوص الكبد ، تجمعات دهنية في الخلايا مع اضمحلال النواة في بعض منها ، ردوب للقناة المرارية ، وازدياد الخلايا الدائرية في أماكن الإصابة لكل من الجرذان المعاملة بالفينفاليرات أو الفوسفولان . أدت طول فترة المعاملة والجرعات المستخدمة إلى ازدياد المرض الكبدي .

كما أظهرت الفحوص النسيجية لكبد الأبناء المولودين لمهات معاملة بالفينفاليرات أو الفوسفولان وجود تآكل لأجزاء متفرقة من خلايا الكبد مصحوبة بتجمع من خلايا دفاعية .

٢ - الكلى

أدت معاملة عذاري الرات بالفينفاليرات أو الفوسفولان لمدة شهرين إلى اضمحلال لأجزاء من الكلية مع ضمور أنابيبها وتغلط مصفاة بومان ووجود حويصلات كلوية مع تليفات بينية . وصاحب المعاملة بالفوسفولان أكثر التأثيرات ضرراً .

لوحظ في الأبناء المولودين لحوامل معاملة بالفينفاليرات عطب في الخلايا الطلائية لأنابيب الكلية في الجرعات المنخفضة وضمور الأنابيب الكلوية وأجسام ملبنيجي في الجرعات العالية ، في حين أحدثت كل من جرعتي الفوسفولان ضمور لأنابيب الكلية مع اختفاء العديد منها .

٣ - المبيض

أحدثت المعاملة بكل من الفينفاليرات والفوسفولان تناقص في البويضات في حين استبدلت الحويصلات البيضبة بتليف زجاجي بعد أربعة أشهر من المعاملة بالفينفاليرات .

٤ - الرحم

أحدثت المعاملة بكل المبيدين ضمور حويصلي لغدد الرحم التي بدت غير إفرازية كما لوحظ وجود مناطق نزيف دموية في أجزاء من الرحم .